

Ultrasound-guided Brachial Plexus Block as a Sole Anaesthetic Technique in a Child for Fixation of Humerus Fracture: A Case Report

S PARTHASARATHY¹, THALANGARA MUKHTAR ABDULLA²

ABSTRACT

Managing supracondylar fractures provides distinct problems in the complex setting of paediatric trauma. A 36-month-old male child was admitted with accidental injury and supracondylar fracture of left humerus. There were no other injuries. The child was planned open reduction and internal fixation in the right lateral position. The plan was to administer nerve block. To satisfactorily transfer the baby, the authors administered 5 mg of oral diazepam to the mother after explanation. The patient was smoothly transferred inside with syrup promethazine 5 mL. After securing an intravenous access, and an intravenous pethidine of 10 mg, he was administered ultrasound guided brachial plexus block with a supraclavicular approach with 5 mL of 0.5% bupivacaine. The pain subsided and the patient slept well. The surgery and the postoperative period were uneventful. The authors concluded that sedating the mother prior will help in separation and nerve blocks can be administered in children in precise sites with the help of ultrasound but without supplemental general anaesthesia. This report is the first case report to do without the use of any intravenous anaesthetic drugs.

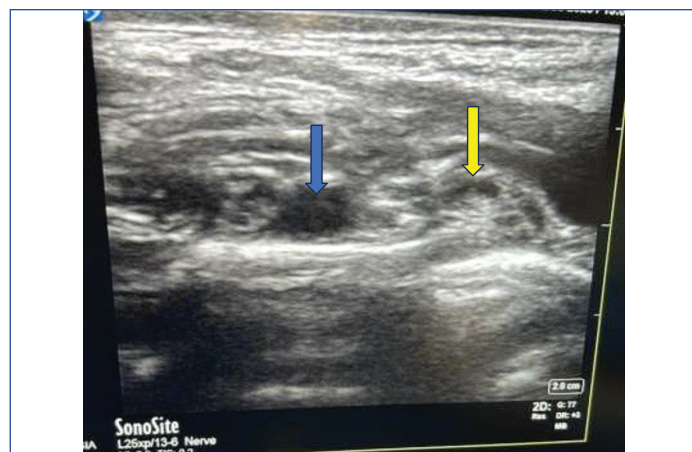
Keywords: Anaesthesia, Anxiolysis, Mother, Nerve block, Paediatric, Separation, Supraclavicular

CASE REPORT

A 36-month-old male child arrived with an incidental injury to the left humerus with a supracondylar fracture. Because there were no other organ injuries, a specific treatment plan using open reduction and internal fixation was possible. After careful discussion, the choice was made to deliver a nerve block, and to help the easy transfer of the kid, 5 mg of oral diazepam was administered to the mother. To facilitate a smooth and anxiety-free transfer, the kid was also given syrup promethazine (5 mL) to aid in the sedative process. After gaining a smooth intravenous access, 10 mg of intravenous pethidine was provided.

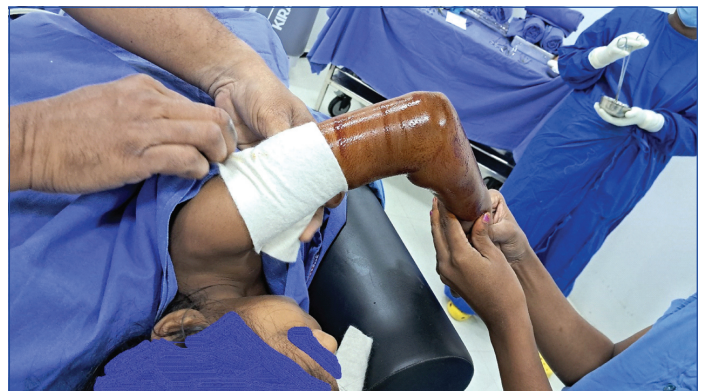Ultrasound-guided brachial plexus block: The administration of an ultrasound-guided brachial plexus block via a supraclavicular route is the basis of this case's success. The goal to reduce the hazards associated with general anaesthesia in paediatric patients drove the choice to use a nerve block instead of additional general anaesthesia. The block was done with ultrasound guidance, (Sono site X Porte) which ensured precision and safety [Table/Fig-1].

An injection of 5 mL of 0.5% bupivacaine into the brachial plexus effectively inhibited both the sensory and motor pathways, resulting



[Table/Fig-1]: Subclavian Artery (SA) (marked in blue) and Brachial Plexus (BP) (marked in yellow).

in considerable pain relief. This method not only offered enough pain relief, but also allowed the child to fall asleep [Table/Fig-2], which contributed to the ease of the surgical procedure.



[Table/Fig-2]: Well sedated patient without any gas administration and initiation of surgical procedure.

Sedation for effective separation: The mother's administration of diazepam was critical in the child's calm separation for the surgery. The sedative enabled a smooth handover of care by reducing the mother's anxiety and fostering a quiet setting (unpublished – author's personal experience). This deliberate use of sedation highlights the necessity of a comprehensive approach to paediatric trauma management, recognising the interconnectivity of the child's well-being and the caregiver's part in the process.

Finally, a multifaceted approach was used to successfully manage a supracondylar humerus fracture in a 36 to 40-month-old child. Sedation of the mother aided separation, and ultrasound-guided brachial plexus block emerged as a reliable alternative to general anaesthesia. The parents consented for publication without disclosing the identity.

DISCUSSION

In the intricate realm of paediatric trauma, supracondylar fractures pose unique challenges, particularly in children aged 36 to 40 months [1]. The present case study explores an innovative

approach to treating such fractures, highlighting the crucial roles of sedation for both the child and the mother, alongside ultrasound-guided brachial plexus block, for effective management. Yang CW et al., have reported four cases of paediatric supraclavicular brachial plexus block in children and used ultrasound to guide the needle and completed the cases without complications [2]. Altinay M et al., have described 24 cases of such blocks in children [3]. Castillo-Zamora C and Castillo-Peralta LA have done brachial plexus block in 283 children successfully [4]. Yet all these studies have not commented about mother separation and all children were deeply sedated or done with general anaesthesia, we did it with minimal sedation and the child was conscious throughout the surgery. The sedation the child had was because of intense analgesia.

Outcomes: The child was normal after the surgery, which lasted for 90 minutes and was discharged on the second day with complete recovery of neurological blockade in 18 hours.

CONCLUSION(S)

An approximately three and half-year-old child with fracture of the humerus was separated from the mother by adding diazepam to

the mother. The mother child separation was possible with maternal reduction of anxiety. Even a mild sedation with precise ultrasound guided supraclavicular block for the child was sufficient to produce deep sleep as the block produced intense analgesia. The present report is the first case report to do without the use of any intravenous anaesthetic drugs.

REFERENCES

- [1] Amiri HR, Espandar R. Upper extremity surgery in younger children under ultrasound-guided supraclavicular brachial plexus block: A case series. *J Child Orthop.* 2010;4(4):315-19. Doi: 10.1007/s11832-010-0264-8.
- [2] Yang CW, Cho CK, Kwon HU, Roh JY, Heo YM, Ahn SM. Ultrasound-guided supraclavicular brachial plexus block in pediatric patients -A report of four cases-. *Korean J Anaesthesiol.* 2010;59(Suppl):S90-94. Doi: 10.4097/kjae.2010.59.S.S90.
- [3] Altinay M, Turk HS, Ediz N, Talmac MA, Oba S. Our ultrasound guided brachial plexus block experiences for upper extremity surgeries in pediatric patients. *Sisli Etfal Hastan Tip Bul.* 2020;54(2):231-35. Doi: 10.14744/SEMB.2018.98958.
- [4] Castillo-Zamora C, Castillo-Peralta LA. Brachial plexus block with ultrasound: A descriptive study of routine clinical practice in 283 children. *Rev Mex Anest.* 2023;46(1):21-25. Doi: 10.35366/108618.

PARTICULARS OF CONTRIBUTORS:

1. Professor, Department of Anaesthesiology, Mahatma Gandhi Medical College and Research Institute, Sri Balaji Vidyapeeth, Puducherry, India.
2. Research Scholar, Department of Anaesthesiology, Mahatma Gandhi Medical College and Research Institute, Sri Balaji Vidyapeeth, Puducherry, India.

NAME, ADDRESS, E-MAIL ID OF THE CORRESPONDING AUTHOR:

Thalagara Mukhthar Abdulla,
Research Scholar, Department of Anaesthesiology, Mahatma Gandhi Medical
College and Research Institute, Sri Balaji Vidyapeeth, Puducherry-607402, India.
E-mail: tmuqtar8@gmail.com

PLAGIARISM CHECKING METHODS: [Jain H et al.]

- Plagiarism X-checker: Jan 31, 2024
- Manual Googling: Feb 26, 2024
- iThenticate Software: Mar 12, 2024 (7%)

ETYMOLOGY: Author Origin

EMENDATIONS: 5

AUTHOR DECLARATION:

- Financial or Other Competing Interests: None
- Was informed consent obtained from the subjects involved in the study? Yes
- For any images presented appropriate consent has been obtained from the subjects. Yes

Date of Submission: **Jan 30, 2024**

Date of Peer Review: **Feb 23, 2024**

Date of Acceptance: **Mar 01, 2024**

Date of Publishing: **Apr 01, 2024**